



THE COLLEGE OF
OPTOMETRISTS

Stage Two

Overarching case scenario 12

AGE AND GENDER Male Aged 36 years

ETHNIC BACKGROUND Caucasian

OCCUPATION AND HOBBIES Recruitment Consultant: VDU user 4 hours daily: Driver: Football and squash

PRESENTING SYMPTOMS AND HISTORY Hit in the face with a squash ball last week, no problems until yesterday when noticed a blurry patch in vision of LE. Always had some floaters but this patch is different. No curtain or veil noticed. No flashes reported.

Spectacles worn constantly, 2 years old, distance and near vision good. Generally, but this blurry patch is causing problems with vision. No family history of eye problems.

GENERAL HEALTH AND MEDICATION Good, no medication. No allergies

PRESENT Rx, CENTRATION AND ACUITIES CR39 single vision: frame and lenses in good condition

RE: -4.25DS

LE: -3.75 DS ocd 63

Distance RE: 6/9 LE: 6/5 Near RE: N5 LE: N5

PD/NCD 63/60 at 40cm

VISION RE: 3/60 LE: 3/60

PINHOLE VISION RE: 6/9 LE: 6/9+2

REFRACTION

RE: -4.25/-0.25 x 180

LE: -3.75/-0.25 x 180

VA

Distance RE: 6/9+2 LE: 6/5

Near RE: N5 LE: N5

ACCOMMODATION RE: 6.0 LE: 8.0 Binoc: 8.0

BINOCULAR STATUS

No movement detected at distance or near

MOTILITY full to all extremes, no pain or diplopia

PUPIL REACTIONS direct, consensual and near reflexes present. No RAPD

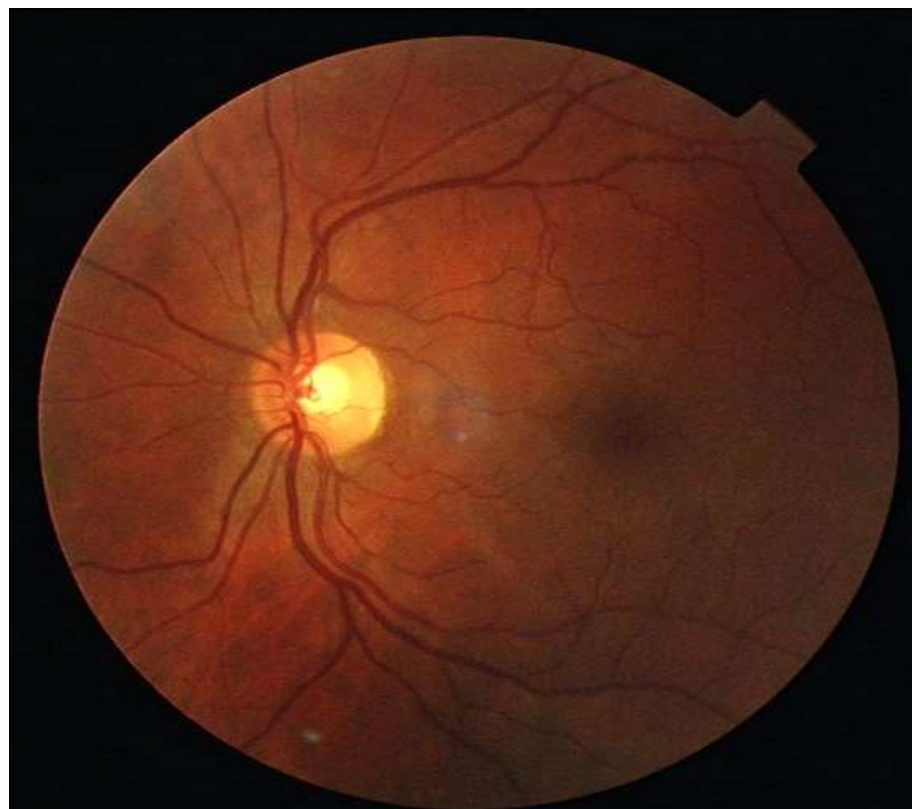
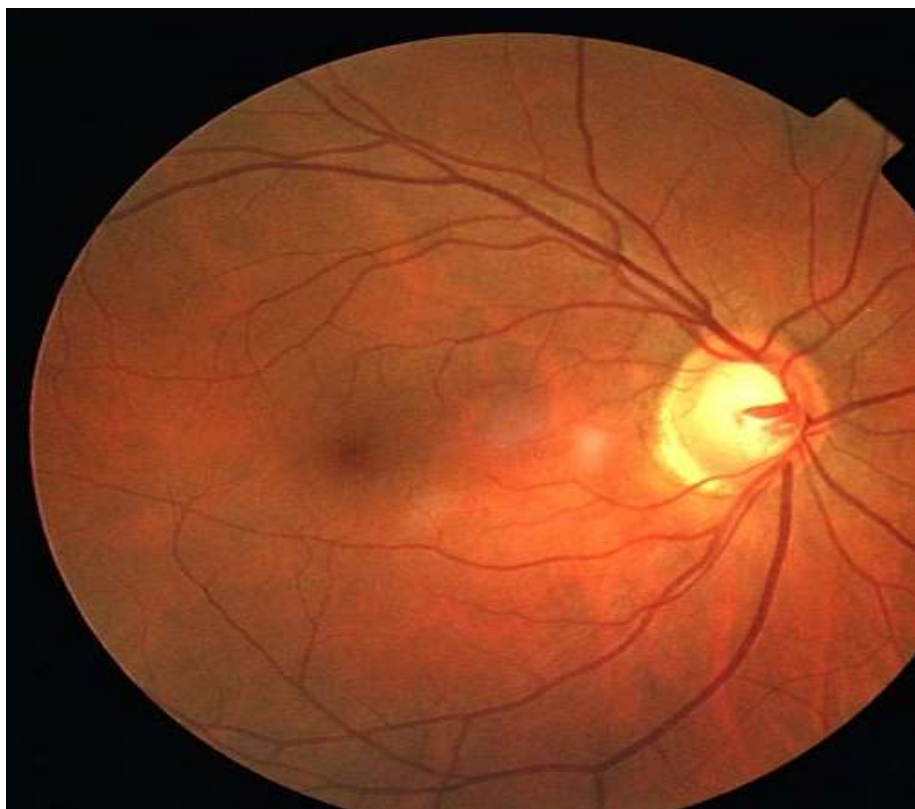
FUNDUS EXAMINATION see attached

FIELDS see attached

IOP NCT RE: 31, 30, 30, 29 mmHg LE: 15,14,15,15 mmHg 10am

EXTERNAL EYE EXAMINATION all healthy R&L

Fundus Image



Field RE & LE

